

# The NEW ENGLAND JOURNAL of MEDICINE

ESTABLISHED IN 1812

DECEMBER 4, 2003

VOL. 349 NO. 23

## Computed Tomographic Virtual Colonoscopy to Screen for Colorectal Neoplasia in Asymptomatic Adults

Perry J. Pickhardt, M.D., J. Richard Choi, Sc.D., M.D., Inku Hwang, M.D., James A. Butler, M.D.,  
Michael L. Puckett, M.D., Hans A. Hildebrandt, M.D., Roy K. Wong, M.D., Pamela A. Nugent, M.D.,  
Pauline A. Mysliwiec, M.D., M.P.H., and William R. Schindler, D.O.

### ABSTRACT

#### BACKGROUND

We evaluated the performance characteristics of computed tomographic (CT) virtual colonoscopy for the detection of colorectal neoplasia in an average-risk screening population.

#### METHODS

A total of 1233 asymptomatic adults (mean age, 57.8 years) underwent same-day virtual and optical colonoscopy. Radiologists used the three-dimensional endoluminal display for the initial detection of polyps on CT virtual colonoscopy. For the initial examination of each colonic segment, the colonoscopists were unaware of the findings on virtual colonoscopy, which were revealed to them before any subsequent reexamination. The sensitivity and specificity of virtual colonoscopy and the sensitivity of optical colonoscopy were calculated with the use of the findings of the final, unblinded optical colonoscopy as the reference standard.

#### RESULTS

The sensitivity of virtual colonoscopy for adenomatous polyps was 93.8 percent for polyps at least 10 mm in diameter, 93.9 percent for polyps at least 8 mm in diameter, and 88.7 percent for polyps at least 6 mm in diameter. The sensitivity of optical colonoscopy for adenomatous polyps was 87.5 percent, 91.5 percent, and 92.3 percent for the three sizes of polyps, respectively. The specificity of virtual colonoscopy for adenomatous polyps was 96.0 percent for polyps at least 10 mm in diameter, 92.2 percent for polyps at least 8 mm in diameter, and 79.6 percent for polyps at least 6 mm in diameter. Two polyps were malignant; both were detected on virtual colonoscopy, and one of them was missed on optical colonoscopy before the results on virtual colonoscopy were revealed.

#### CONCLUSIONS

CT virtual colonoscopy with the use of a three-dimensional approach is an accurate screening method for the detection of colorectal neoplasia in asymptomatic average-risk adults and compares favorably with optical colonoscopy in terms of the detection of clinically relevant lesions.

From the Departments of Radiology (P.J.P., P.A.N.) and Gastroenterology (J.A.B., P.A.M.), National Naval Medical Center; the Department of Radiology, F. Edward Hébert School of Medicine, Uniformed Services University of the Health Sciences (P.J.P., M.L.P.); and the National Cancer Institute, Division of Cancer Prevention (P.A.M.) — all in Bethesda, Md.; the Departments of Radiology (J.R.C.) and Gastroenterology (I.H., R.K.W.), Walter Reed Army Medical Center, Washington, D.C.; and the Departments of Radiology (M.L.P., H.A.H.) and Gastroenterology (W.R.S.), Naval Medical Center San Diego, San Diego, Calif. Address reprint requests to Dr. Pickhardt at the University of Wisconsin Medical School, Department of Radiology, E3/311 Clinical Science Center, 600 Highland Ave., Madison, WI 53792-3252, or at [ppickhardt@mail.radiology.wisc.edu](mailto:ppickhardt@mail.radiology.wisc.edu).

N Engl J Med 2003;349:2191-200.  
Copyright © 2003 Massachusetts Medical Society.

**C**OLORECTAL CANCER IS THE SECOND leading cause of cancer-related deaths in the United States, accounting for nearly 60,000 deaths each year.<sup>1</sup> Most colorectal cancers are believed to arise within benign adenomatous polyps that develop slowly over the course of many years.<sup>2</sup> Evidence-based guidelines recommend the screening of adults who are at average risk for colorectal cancer,<sup>3</sup> since the detection and removal of adenomas have been shown to reduce both the incidence of cancer and cancer-related mortality.<sup>4-6</sup> Unfortunately, about half the average-risk population of the United States has not been screened by any method for this largely preventable disease.<sup>7</sup>

Virtual colonoscopy is a rapidly evolving technique in which data from computed tomography (CT) are used to generate both two-dimensional and three-dimensional displays of the colon and rectum.<sup>8</sup> This minimally invasive method for the examination of the whole colon, also called CT colonography, could provide an attractive alternative for use in widespread screening, since it requires no intravenous administration of sedatives, analgesia, or recovery time. Although the performance characteristics of virtual colonoscopy have been encouraging in trials involving cohorts of patients with an increased number of polyps,<sup>9,10</sup> the results in populations with a lower prevalence of polyps have been disappointing, and the large studies conducted to date have not evaluated an asymptomatic, average-risk screening population.<sup>11-15</sup> We conducted a prospective study to evaluate the performance characteristics of virtual colonoscopy in a typical asymptomatic screening population; we used a three-dimensional approach to the study and interpretation of the radiographic images.

## METHODS

### STUDY GROUP

The study protocol was approved by the institutional review board at each participating center. Patients were recruited primarily through referrals for screening colonoscopy (in asymptomatic patients). Written informed consent was obtained from all patients. Adults between 50 and 79 years of age with an average risk of colorectal cancer (and adults 40 to 79 years of age with a family history of colorectal cancer) made up the primary study group. The criteria for exclusion are listed in Table 1. Between May 2002 and June 2003, 1233 asymptomatic adults at three medical centers underwent same-day virtual and optical colonoscopy.

### STUDY DESIGN

The enrolled patients completed a detailed questionnaire regarding their personal and family medical history. Patients underwent standard 24-hour colonic preparation with the oral administration of 90 ml of sodium phosphate (Fleet 1 preparation, Fleet Pharmaceuticals) and 10 mg of bisacodyl. As part of their clear-liquid diet, patients also consumed 500 ml of barium (2.1 percent by weight; Scan C, Lafayette Pharmaceuticals) for solid-stool tagging and 120 ml of diatrizoate meglumine and diatrizoate sodium (Gastrografin, Bracco Diagnostics) for the opacification of luminal fluid.<sup>16</sup>

Our CT protocol was as follows. On the insertion of a small flexible rectal catheter, pneumocolon was achieved through the patient-controlled insufflation of room air immediately before scanning. CT scanning was performed while the patient held his or her breath in the supine and prone positions; a four-channel or eight-channel CT scanner was used (GE LightSpeed or LightSpeed Ultra, General Electric Medical Systems). The CT technique involved the use of 1.25-to-2.5-mm collimation, a table speed of 15 mm per second, a reconstruction interval of 1 mm, and scanner settings of 100 mAs and 120 kV<sub>p</sub>.

Image processing and interpretation were performed with the use of a commercially available CT colonographic system (Viatronix V3D Colon, version 1.2, Viatronix). This software program extracts the images of the air-filled colon, generates an automated centerline for luminal navigation (Fig. 1A), and electronically removes from images the opacified residual fluid in a routine postprocessing step. The diagnostic interface allows for a virtual “fly-through” tour of the three-dimensional image (Fig. 1B and Supplementary Appendix 1 [available with the full text of this article at [www.nejm.org](http://www.nejm.org)]) and rapid correlation with the two-dimensional images for any suspected abnormality (Fig. 1C). Although both the two-dimensional view and the three-dimensional view were used, the latter was relied on for the initial detection of polyps. Polyps were measured with electronic calipers on the three-dimensional view and recorded according to the segment (cecum, ascending colon, hepatic flexure, transverse colon, splenic flexure, descending colon, sigmoid colon, or rectum). Extracolonic findings on CT were also recorded and categorized as representing a condition of potentially high, moderate, or low clinical importance, in a manner similar to that used in previously reported studies.<sup>17,18</sup>

CT virtual colonoscopic studies were interpret-

ed prospectively by one of six board-certified radiologists immediately before the optical examination. All radiologists had received training involving the reading of a minimum of 25 virtual colonoscopic studies; two of the radiologists had previously interpreted more than 100 such studies each.

Optical colonoscopy was performed by 17 experienced colonoscopists (14 gastroenterologists and 3 colorectal surgeons) who were initially unaware of the results of the virtual colonoscopy. A standard commercial video colonoscope (Olympus) was inserted into the cecum and sequentially withdrawn segment by segment for the detection of polyps. Polyps were photographed (Fig. 1D) and measured with the use of a calibrated linear probe, which is more accurate than either visual estimation or estimation with the use of open biopsy forceps.<sup>19</sup> After the colonoscopist completed the evaluation of a given segment of the colon, a study coordinator revealed the results of the virtual colonoscopy for the previously examined segment. If a polyp measuring 5 mm or more in diameter was seen on virtual colonoscopy but not on the initial optical colonoscopy, the colonoscopist closely reexamined that segment and was allowed to review the images obtained on virtual colonoscopy for guidance. This “segmental unblinding” resulted in the creation of an enhanced reference standard and allowed for the assessment of false negative results on optical colonoscopy that would otherwise have been recorded as false positive results on virtual colonoscopy. All polyps that were retrieved were sent for histologic evaluation.

The time spent by each patient in the CT suite, the endoscopy suite, and the recovery area was recorded. The time required for the interpretation of virtual colonoscopic studies was also recorded. At discharge, all study patients were given a one-page questionnaire to complete at home and return by mail. The questionnaire assessed the levels of discomfort and overall convenience, as well as the preference for the use of virtual or optical colonoscopy in the future.

#### STATISTICAL ANALYSIS

The final results on optical colonoscopy, which included findings after the reexaminations informed by the results on virtual colonoscopy, served as the reference standard with which the results of virtual colonoscopy and the initial optical colonoscopy were compared. Of primary interest were adenomatous polyps measuring 6 mm or more in diameter. Advanced neoplasia was defined as any adenoma

**Table 1. Criteria for Exclusion.**

Positive guaiac-based test of stool within 6 mo before referral
Iron-deficiency anemia within previous 6 mo
Rectal bleeding or hematochezia within previous 12 mo
Unintentional weight loss of more than 10 lb (4.5 kg) within previous 12 mo
Optical colonoscopy within previous 10 yr
Barium enema within previous 5 yr
History of adenomatous polyps, colorectal cancer, or inflammatory bowel disease
History of familial adenomatous polyposis or hereditary nonpolyposis cancer syndromes
Rejection for optical colonoscopy for any reason
Medical condition that precludes the use of sodium phosphate preparation
Pregnancy

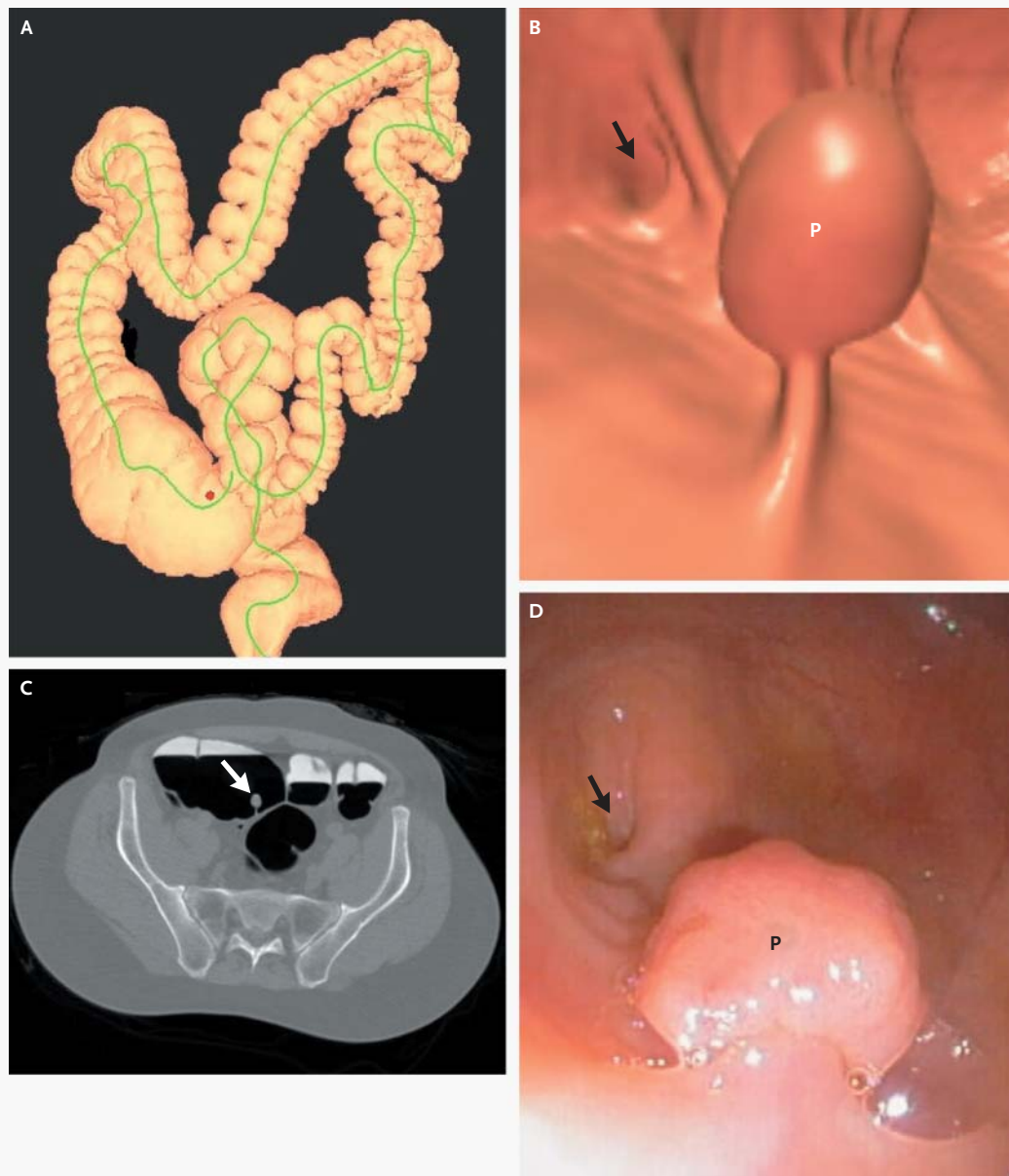
measuring 10 mm or more in diameter or demonstrating high-grade dysplasia, a prominent villous component, or a focus of cancer.<sup>20</sup> Nonadenomatous lesions (such as hyperplastic polyps) and diminutive polyps ( $\leq 5$  mm in diameter) were of secondary interest.

A polyp-matching algorithm was used to address inherent uncertainties in the comparison of localizations and sizes. For a given polyp to be considered a true positive match between virtual and optical colonoscopy, it had to be assessed as appearing within the same segment or in adjacent segments, and the two recorded diameters had to be the same, within a 50 percent margin of error. For a patient to be considered to have a true positive result for a polyp in a given size category, at least one polyp of that size or larger had to be present on both virtual and optical colonoscopy. Given the relatively low prevalence of disease, polyp matching in this cohort was generally not problematic.

Tests of significance included McNemar's test, Fisher's exact test, chi-square tests, or paired t-tests, as appropriate. To assess interobserver agreement, 100 randomly selected virtual colonoscopic studies were interpreted retrospectively by a second study radiologist at a different center. Interobserver reliability was measured with the use of the kappa statistic.

#### RESULTS

Of 1253 consecutively enrolled asymptomatic adults, 1233 underwent complete virtual and optical colonoscopic examinations (728 men and 505 women; mean age, 57.8 years). Eight patients were excluded because of incomplete optical colonoscopy (for a rate of completion of 99.4 percent). Twelve patients were excluded because of inadequate prep-



**Figure 1. Solitary 16-mm Pedunculated Cecal Polyp in a 55-Year-Old Man at Average Risk for Colorectal Neoplasia.**

Panel A shows a schematic map of the air-filled colon generated from the computed tomographic (CT) scan obtained with the patient in the prone position. The green line is the centerline that is automatically generated for virtual navigation; the red dot is a “bookmark” indicating the location of the polyp within the cecum. Panel B, a three-dimensional view from the endoluminal “fly-through” generated from the same CT scan, shows the cecal polyp (P) and the appendiceal orifice (arrow) in the background. This display was used for the primary detection of polyps. Panel C is an axial, two-dimensional CT image obtained with the patient in the prone position; it shows the polyp (arrow) on a stalk within the air-filled cecum. The residual luminal fluid is opacified by oral contrast agent, which enables the software program to “cleanse” the three-dimensional image. This two-dimensional display was used for the confirmation of suspected findings on the three-dimensional view. Panel D is a digital photograph from optical colonoscopy performed immediately after CT virtual colonoscopy; it shows the cecal polyp (P) and the appendiceal orifice (arrow). Histologic examination revealed that the polyp was adenomatous.

aration (in six patients) or failure of the CT colonographic system (in six patients). Thirty-two of the 1233 study patients had either a first-degree relative with colorectal cancer diagnosed before 60 years of age or two first-degree relatives with colorectal cancer diagnosed at any age, either of which confers a higher-than-average risk of neoplasia.<sup>3,21</sup> The remaining 1201 patients (97.4 percent) were considered to be at average risk. There were no clinically significant complications after virtual colonoscopy; one patient was hospitalized for delayed bleeding after a polypectomy performed during optical colonoscopy.

Table 2 summarizes the distribution of polyps according to size and location in this asymptomatic population; these are the final results based on the unblinded optical colonoscopy. The prevalence of adenomatous polyps 10 mm or more in diameter was 3.9 percent; the prevalence of adenomatous polyps 8 mm or more in diameter was 6.7 percent; and the prevalence of adenomatous polyps 6 mm or more in diameter was 13.6 percent. There was no significant difference in the prevalence of adenomas between the patients with average risk and those with above-average risk. Two of the 554 adenomas found (0.4 percent) were malignant. One of the 966 diminutive polyps found ( $\leq 5$  mm in diameter; 0.1 percent) was classified as advanced (a 4-mm tubular adenoma with villous features).

Table 3 shows the diagnostic performance of virtual colonoscopy (and optical colonoscopy before unblinding) according to the size category for the analyses both according to the patient and according to the polyp. Of the 55 additional polyps at least 5 mm in diameter that were detected on optical colonoscopy after the colonoscopists were shown the results from the virtual colonoscopy, 21 were adenomatous and at least 6 mm in diameter. In the analysis according to the polyp, the sensitivity of virtual colonoscopy for all advanced neoplasms was 91.5 percent (54 of 59), and the sensitivity of the initial optical colonoscopy for all advanced neoplasms was 88.1 percent (52 of 59). Both adenocarcinomas were detected on virtual colonoscopy, whereas one cancer (an 11-mm malignant polyp) was missed on optical colonoscopy before unblinding. In both the analysis according to the polyp and the analysis according to the patient, the sensitivity of virtual colonoscopy was slightly higher than that of optical colonoscopy for adenomatous polyps of 8 mm or larger, but the differences were not statistically significant ( $P=0.31$  to 0.56).

**Table 2. Distribution of Adenomatous and Nonadenomatous Polyps According to Size and Location in 1233 Asymptomatic Adults.\***

Variable	Polyp Size			
	$\leq 5$ mm	6–9 mm	$\geq 10$ mm	Any
	number of polyps			
Rectum				
Adenomatous	28	17	10	55
Nonadenomatous	167	24	4	195
Sigmoid colon				
Adenomatous	75	46	7	128
Nonadenomatous	192	31	8	231
Descending colon				
Adenomatous	39	18	6	63
Nonadenomatous	51	8	1	60
Splenic flexure				
Adenomatous	11	5	2	18
Nonadenomatous	27	5	2	34
Transverse colon				
Adenomatous	47	29	3	79
Nonadenomatous	60	5	4	69
Hepatic flexure				
Adenomatous	29	8	0	37
Nonadenomatous	28	5	1	34
Ascending colon				
Adenomatous	73	23	16	112
Nonadenomatous	60	20	8	88
Cecum				
Adenomatous	42	13	7	62
Nonadenomatous	37	5	3	45
Total				
Adenomatous	344	159	51	554
Nonadenomatous	622	103	31	756

\* A total of 611 of the 1233 patients had no polyps. Two polyps, located in the cecum and the ascending colon, were malignant.

For adenomatous polyps measuring 8 mm or more in diameter, the overall accuracy of virtual colonoscopy in the analysis according to the patient exceeded 92 percent, and it was nearly 96 percent for adenomatous polyps measuring 10 mm or more in diameter. The negative predictive value of virtual colonoscopy was more than 99 percent for adenomatous polyps measuring 8 mm or more in diameter. The diagnostic performance of virtual colonoscopy was uniform in all centers. For example, for adenomatous polyps measuring 8 mm or more in diameter, the sensitivity of virtual colonoscopy in the analysis according to the patient ranged from 92.9 to 94.9 percent, and its specificity ranged from 91.0 to 93.8 percent.

The specificity for adenomas in the analysis ac-

**Table 3. Performance Characteristics of Virtual Colonoscopy and Optical Colonoscopy for the Detection of Adenomas.\***

Variable	Size Category				
	≥6 mm	≥7 mm	≥8 mm	≥9 mm	≥10 mm
	no./total no. (% [95% CI])				
<b>Analysis according to patient</b>					
Virtual colonoscopy					
Sensitivity	149/168 (88.7 [82.9–93.1])	100/110 (90.9 [83.9–95.6])	77/82 (93.9 [86.3–98.0])	53/57 (93.0 [83.0–98.1])	45/48 (93.8 [82.8–98.7])
Specificity	848/1065 (79.6 [77.0–82.0])	981/1123 (87.4 [85.3–89.2])	1061/1151 (92.2 [90.5–93.7])	1116/1176 (94.9 [93.5–96.1])	1138/1185 (96.0 [94.8–97.1])
Accuracy	997/1233 (80.9 [78.6–83.0])	1081/1233 (87.7 [85.7–89.5])	1138/1233 (92.3 [90.7–93.7])	1169/1233 (94.8 [93.4–96.0])	1183/1233 (95.9 [94.7–97.0])
Test-positive rate†	366/1233 (29.7 [27.1–32.3])	242/1233 (19.6 [17.4–22.0])	167/1233 (13.5 [11.7–15.6])	113/1233 (9.2 [7.6–10.9])	92/1233 (7.5 [6.1–9.1])
Sensitivity of optical colonoscopy					
	155/168 (92.3 [87.1–95.8])	100/110 (90.9 [83.9–95.6])	75/82 (91.5 [83.2–96.5])	51/57 (89.5 [78.5–96.0])	42/48 (87.5 [74.8–95.3])
<b>Analysis according to polyp</b>					
Sensitivity of virtual colonoscopy					
	180/210 (85.7 [80.2–90.1])	119/133 (89.5 [83.0–94.1])	88/95 (92.6 [85.4–97.0])	56/61 (91.8 [81.2–97.3])	47/51 (92.2 [81.1–97.8])
Sensitivity of optical colonoscopy					
	189/210 (90.0 [85.1–93.7])	120/133 (90.2 [83.9–94.7])	85/95 (89.5 [81.5–94.8])	55/61 (90.2 [79.8–96.3])	45/51 (88.2 [76.1–95.6])

\* The data for optical colonoscopy are for the initial optical colonoscopy performed before the results on virtual colonoscopy were revealed. CI denotes confidence interval.

† Data are for the virtual colonoscopic studies that were deemed to be positive in each size category.

according to the patient that is shown in Table 3 reflects the fact that matches with nonadenomatous polyps were considered to represent false positive results. This effect was greatest in lower size categories, in which hyperplastic polyps predominate. If all matched polyps were considered to represent true positive results, regardless of histologic features, the corresponding specificity of virtual colonoscopy in an analysis according to the patient would be 97.4 percent (1131 of 1161) for polyps 10 mm or larger, 95.0 percent (1050 of 1105) for polyps 8 mm or larger, and 84.5 percent (826 of 978) for polyps 6 mm or larger.

The summation of the true positive and false positive rates with virtual colonoscopy yields a “test positive rate” that is an important consideration for the development of a screening algorithm. Not surprisingly, this indicator is highly dependent on the size category (Table 3). For example, if the cutoff had been 10 mm, 1 of every 13.4 patients (7.5 percent), on average, would have been referred for polypectomy.

There was good interobserver agreement on the virtual colonoscopic studies that were read twice, with a segmental agreement rate of 99.6 percent

(797 of 800 polyps) for polyps 10 mm or larger, 99.1 percent (793 of 800) for polyps 8 mm or larger, and 97.6 percent (781 of 800) for polyps 6 mm or larger ( $\kappa=0.75$  to 0.80). Agreement according to the patient was 95 percent for polyps 8 mm or larger ( $\kappa=0.79$ ).

There were extracolonic findings on CT of potentially high clinical importance in 56 patients (4.5 percent). Unsuspected extracolonic cancer, however, was subsequently proven in only five patients (0.4 percent): one with lymphoma, two with bronchogenic carcinoma, one with ovarian carcinoma, and one with renal-cell carcinoma. Two patients subsequently underwent successful repair of unsuspected abdominal aortic aneurysms. Extracolonic findings on CT of moderate clinical importance were more frequent, including nephrolithiasis in 98 patients (7.9 percent) and gallstones in 69 patients (5.6 percent).

The mean time spent by patients in the CT suite was 14.1 minutes, as compared with 31.5 minutes in the endoscopy suite ( $P<0.001$ ). It was occasionally necessary for a patient to spend additional time in the endoscopy suite for segmental reexamination after the colonoscopist was shown the results of

virtual colonoscopy, but this time was most likely a minor contributor to the total duration. Including the time for recovery after sedation, the mean time spent by patients undergoing optical colonoscopy was 95.9 minutes. The mean time required for the interpretation of virtual colonoscopic studies (including the evaluation of extracolonic findings) was 15.9 minutes, 17.1 minutes, and 24.0 minutes in the three centers, respectively. The overall mean time required for interpretation was 19.6 minutes (median, 18.0), but it decreased to 16.9 minutes (median, 15.0) for the second half of the study. The mean time required for interpretation in the retrospective second readings (which did not include the evaluation of extracolonic findings) was 8.0 minutes.

A total of 1005 of the 1233 patients returned their post-study questionnaires (81.5 percent). Overall, more patients recalled greater discomfort associated with virtual colonoscopy (546 patients, 54.3 percent) than recalled greater discomfort associated with optical colonoscopy (383 patients, 38.1 percent,  $P < 0.001$ ); 76 patients (7.6 percent) were undecided or indicated that both studies were equivalent with regard to comfort. However, only 82 patients (8.2 percent) rated the discomfort associated with virtual colonoscopy as severe. (The rates of recall of discomfort were probably affected by sedation, which was used only for optical colonoscopy.) Most patients still found virtual colonoscopy more acceptable in terms of overall convenience: 686 of the patients who returned the questionnaire (68.3 percent) rated virtual colonoscopy as more acceptable than optical colonoscopy, and 242 patients (24.1 percent) rated optical colonoscopy as more acceptable than virtual colonoscopy ( $P < 0.001$ ); 77 patients (7.7 percent) rated the tests as equivalent or were undecided. More patients indicated that they would prefer virtual colonoscopy to optical colonoscopy for future screening: 500 patients (49.8 percent) preferred virtual colonoscopy, and 413 patients (41.1 percent) preferred optical colonoscopy ( $P = 0.004$ ); 92 patients (9.2 percent) had no preference or were undecided. There was an unintended bias that increased the number of responses for optical colonoscopy in that at least some of the patients who had polyps removed assumed that such polypectomy would therefore be indicated. In fact, the great majority of these polyps were diminutive, and referral from virtual to optical colonoscopy would not be indicated in actual practice. More than 90 percent of respondents rated their level of satisfaction with virtual colonoscopy as “ex-

cellent” (40.6 percent), “very good” (32.8 percent), or “good” (17.9 percent), whereas 6.3 percent and 2.4 percent rated their satisfaction as “fair” and “poor,” respectively.

---

## DISCUSSION

---

Virtual colonoscopy is a promising tool for screening for colorectal cancer. Its performance characteristics have been encouraging in populations with a high prevalence of colorectal neoplasia,<sup>9,10</sup> but the initial results of studies using a primary two-dimensional approach (with three-dimensional views reserved for problem solving) in populations with a low prevalence of colorectal neoplasia have been disappointing.<sup>11,12</sup> However, when a primary three-dimensional approach for the detection of polyps is applied (with two-dimensional views used chiefly for correlation), our results indicate that this minimally invasive examination of the whole colon is also an accurate method for the screening of asymptomatic adults who have an average risk of colorectal cancer. Virtual colonoscopy not only had high sensitivity, but also maintained acceptable specificity for adenomas that were more than 6 mm in diameter, despite the application of a more stringent size-based algorithm than others have used<sup>10,22</sup> and the classification of matched nonadenomatous polyps as false positive results. Our justification for “penalizing” virtual colonoscopy for matched nonadenomatous polyps was that, since these lesions have no malignant potential, polypectomy would not be of benefit. It is important to remember that adenomas (particularly advanced lesions) are the primary target of screening.<sup>2,23</sup>

From the standpoint of patient care, it is most useful to consider the results of virtual colonoscopy in terms of the size category of the polyps,<sup>22</sup> allowing the size of the largest polyp detected to determine what next step is appropriate. For screening purposes, guidelines must be set that would stratify patients' needs into such categories as immediate optical colonoscopy for polypectomy, short-term surveillance, and routine follow-up. Most reported studies of virtual colonoscopy have focused on three categories of polyp size: 5 mm or smaller, 10 mm or larger, and 6 to 9 mm.<sup>8-10</sup> There appears to be a consensus (or at least a majority opinion) that diminutive colonic polyps ( $\leq 5$  mm in diameter) should be regarded as clinically insignificant and therefore ignored on virtual colonoscopy.<sup>15,24,25</sup> Only a minority of these small lesions are

adenomatous, and of these, less than 1 percent are histologically advanced and virtually none are malignant.<sup>24</sup> This is fortunate, since the detection of such tiny lesions on virtual colonoscopy and subsequent matching on optical colonoscopy are both unreliable.

The 10-mm polyp has been the benchmark for most trials of virtual and optical colonoscopy to date,<sup>9,10,20,21</sup> and there is some evidence to support its use as a critical threshold. Some authorities posit that “small adenomas” (defined as <10 mm in diameter) have little immediate or long-term clinical significance.<sup>24</sup> As our results and those of others<sup>20</sup> show, relatively few advanced lesions measure less than 10 mm. If clinical legitimacy is assumed, a 10-mm threshold would probably render the use of virtual colonoscopy for screening cost effective, since only about 1 of every 13 average-risk patients would be referred for optical colonoscopy. However, despite its pervasiveness in the literature, there are indications that this cutoff value may be unacceptable to some.<sup>26</sup>

It has been a common practice to report polyps that measure 6 to 9 mm by lumping them into one category.<sup>8-11</sup> However, since the optimal threshold for screening may lie within this range, such a grouping obscures important data. By instead reporting results according to size thresholds, as we have done, one can select an appropriate cutoff that results in the maintenance of both high sensitivity and acceptable specificity.<sup>22</sup> On the basis of our data, 8 mm might be a reasonable threshold for triggering immediate optical colonoscopy, whereas patients with intermediate-size lesions (perhaps 5 to 7 mm) might be best served by the use of short-term virtual surveillance. All other patients could undergo routine follow-up. The appropriate intervals for surveillance would need to be established, but they may be in the range of 2 to 3 years for short-term surveillance and 5 to 10 years for routine surveillance.

The number of asymptomatic patients who would undergo virtual colonoscopy for screening but would not require optical colonoscopy for polypectomy is highly dependent on the size threshold used. For example, at a threshold of 6 mm, 70.3 percent of the patients in our study would not have been sent for immediate polypectomy, but this figure would increase to 86.5 percent at a threshold of 8 mm and to 92.5 percent at a threshold of 10 mm. The likelihood that a clinically significant adenoma would be missed on virtual colonoscopy is very low,

given the high negative predictive values found in our study. Our study results also indicate that the frequency of important extracolonic findings on CT in average-risk adults is less than half that reported in higher-risk populations.<sup>17,18</sup> This finding has important implications for the overall cost effectiveness of virtual colonoscopic screening, since the number of additional diagnostic studies generated would be fewer than previously determined.

The prevalence of adenomas in our study group was lower than that reported in other studies.<sup>20,21</sup> It is unlikely that this difference was related to sub-optimal endoscopic performance, since the rate of completion of optical colonoscopy was high<sup>20,21</sup> and the detection of polyps was further enhanced by the segmental revelation of the results on virtual colonoscopy. We surmise that the general good health and relatively young age of our patients and the relatively large percentage of women in our study population were primary influences.

The implementation of segmental unblinding in our protocol allowed for the secondary assessment of the performance of optical colonoscopy. In fact, this technique resulted in the recategorization of many false positive results on virtual colonoscopy as false negative results on optical colonoscopy. Although optical colonoscopy is highly reliable, it is not an infallible gold standard, since it has been shown that even with back-to-back colonoscopies, 6 percent of adenomas measuring 10 mm or larger are missed.<sup>27</sup> The increased rate at which polyps were missed in our study most likely relates to the use of a different method for comparison (virtual colonoscopy). In fact, most of the polyps that were found on virtual colonoscopy but not on the initial optical colonoscopy were situated behind a colonic fold, which is recognized as a relative blind spot for physical endoscopy but not for virtual endoscopy, because of the multidirectional nature of the latter. This difference underscores the complementarity of these techniques, whose combined use should result in an overall increase in polyp detection. Although only two carcinomas were detected in our asymptomatic population, it is noteworthy that one malignant polyp located on a fold near the hepatic flexure was detected on optical colonoscopy only after the revelation of the results from the virtual colonoscopy.

Results from two other trials of virtual colonoscopy in populations with a relatively low prevalence of colorectal neoplasia have been presented<sup>12</sup> or published<sup>11</sup> recently. Both studies used a primary

two-dimensional approach to interpretation. Neither of the study groups in these studies was a true screening population, since symptomatic patients were not excluded in one study<sup>12,13</sup> and only patients with higher-than-average risk were included in the other.<sup>11</sup> Nevertheless, their results were strikingly different from ours, with an average sensitivity for the detection of polyps measuring 10 mm or larger, in an analysis according to the patient, of only 55 percent in one study and 48 percent in the other. In one study,<sup>12</sup> the retrospective addition of three-dimensional endoluminal fly-through views significantly increased the sensitivity without causing a significant decrease in specificity, which underscores the value of the three-dimensional display for the detection of polyps.

Reasons for the disparity in performance between these studies and our own are probably multifactorial, but the most important difference in methodology is the use of two-dimensional or three-dimensional display for the initial detection of polyps. The conspicuity of polyps and the duration of visualization are both increased with three-dimensional fly-through views, making searches easier.<sup>28</sup> However, the fact that almost all studies of CT colonography to date<sup>10-12,29-31</sup> have used a primarily two-dimensional approach should not be surprising, since most existing software systems are not yet capable of effective primary three-dimensional

evaluation.<sup>28</sup> The introduction of an enhanced reference standard through the use of segmental unblinding also had an effect on the performance characteristics found in our study. Other factors that probably had a positive influence on our results included the use of stool tagging and electronic fluid cleansing, which are not yet in standard use,<sup>16</sup> and the use of only multidetector helical CT scanners, which allow for faster imaging with thinner sections. Furthermore, issues related to the relative experience of the readers and the quality of the images themselves<sup>15</sup> may contribute to the differences between our results and those of others; if so, this highlights the need for dedicated training of radiologists and technologists.

Our results show that virtual colonoscopy with a three-dimensional emphasis is an effective tool for the detection of colorectal neoplasia in asymptomatic adults with an average risk of colorectal cancer. These findings support the concept of a colon-screening center that offers virtual colonoscopy to patients, with the opportunity for same-day or next-day therapeutic optical colonoscopy, if needed. Such an endeavor would require close collaboration among radiologists and gastroenterologists.

Supported by Advances in Medical Practice funds from the Department of Defense.

The views expressed in this article are those of the authors and do not necessarily represent those of the Department of the Navy, the Department of the Army, or the Department of Defense.

#### APPENDIX

In addition to the authors, study personnel consisted of the following persons: Bethesda, Md. — J.A. Allaire, T.R. Scott; Washington, D.C. — S.N. Albert, C.H. Kim, I.M. Feuerstein, J. Chung, Y.-J. Chen; San Diego, Calif. — V.S. Owen, V.L. Tarbell, M. Cayetano; statistical analysis support — C. Olsen, Biostatistics Consulting Center, Uniformed Services University of the Health Sciences, Bethesda, Md.

#### REFERENCES

- Jemal A, Murray T, Samuels A, Ghafoor A, Ward E, Thun MJ. Cancer statistics, 2003. *CA Cancer J Clin* 2003;53:5-26.
- Bond JH. Clinical evidence for the adenoma-carcinoma sequence, and the management of patients with colorectal adenomas. *Semin Gastrointest Dis* 2000;11:176-84.
- Smith RA, Cokkinides V, Eyre HJ. American Cancer Society guidelines for the early detection of cancer, 2003. *CA Cancer J Clin* 2003;53:27-43.
- Mandel JS, Bond JH, Church TR, et al. Reducing mortality from colorectal cancer by screening for fecal occult blood. *N Engl J Med* 1993;328:1365-71. [Erratum, *N Engl J Med* 1993;329:672.]
- Mandel JS, Church TR, Bond JH, et al. The effect of fecal occult-blood screening on the incidence of colorectal cancer. *N Engl J Med* 2000;343:1603-7.
- Winawer SJ, Zauber AG, Ho MN, et al. Prevention of colorectal cancer by colonoscopic polypectomy. *N Engl J Med* 1993;329:1977-81.
- Colorectal cancer test use among persons aged > or = 50 years — United States, 2001. *MMWR Morb Mortal Wkly Rep* 2003; 52:193-6.
- Johnson CD, Dachman AH. CT colonography: the next colon screening examination? *Radiology* 2000;216:331-41.
- Fenlon HM, Nunes DP, Schroy PC III, Barish MA, Clarke PD, Ferrucci JT. A comparison of virtual and conventional colonoscopy for the detection of colorectal polyps. *N Engl J Med* 1999;341:1496-503. [Erratum, *N Engl J Med* 2000;342:524.]
- Yee J, Akerkar GA, Hung RK, Steinauer-Gebauer AM, Wall SD, McQuaid KR. Colorectal neoplasia: performance characteristics of CT colonography for detection in 300 patients. *Radiology* 2001;219:685-92.
- Johnson CD, Harnsen WS, Wilson LA, et al. Prospective blinded evaluation of computed tomographic colonography for screen detection of colorectal polyps. *Gastroenterology* 2003;125:311-9.
- Cotton PB, Durkalski VL, Palesch YY, et al. Virtual colonoscopy: final results from a multicenter study. *Gastrointest Endosc* 2003; 57:AB174. abstract.
- Durkalski VL, Palesch YY, Pineau BC, Vining DJ, Cotton PB. The virtual colonoscopy study: a large multicenter clinical trial designed to compare two diagnostic screening procedures. *Control Clin Trials* 2002;23: 570-83.
- Bond JH. Virtual colonoscopy — promising, but not ready for widespread use. *N Engl J Med* 1999;341:1540-2.
- Dachman AH, Yoshida H. Virtual colonoscopy: past, present, and future. *Radiol Clin North Am* 2003;41:377-93.
- Pickhardt PJ, Choi JH. Electronic cleansing and stool tagging in CT colonography: advantages and pitfalls with primary three-

- dimensional evaluation. *AJR Am J Roentgenol* 2003;181:799-805.
17. Hara AK, Johnson CD, MacCarty RL, Welch TJ. Incidental extracolonic findings at CT colonography. *Radiology* 2000;215:353-7.
18. Gleucker TM, Johnson CD, Wilson LA, et al. Extracolonic findings at CT colonography: evaluation of prevalence and cost in a screening population. *Gastroenterology* 2003;124:911-6.
19. Gopalswamy N, Shenoy VN, Choudhry U, et al. Is in vivo measurement of size of polyps during colonoscopy accurate? *Gastrointest Endosc* 1997;46:497-502.
20. Lieberman DA, Weiss DG, Bond JH, Ahnen DJ, Garewal H, Chejfec G. Use of colonoscopy to screen asymptomatic adults for colorectal cancer. *N Engl J Med* 2000;343:162-8. [Erratum, *N Engl J Med* 2000;343:1204.]
21. Rex DK, Lehman GA, Ulbright TM, et al. Colonic neoplasia in asymptomatic persons with negative fecal occult blood tests: influence of age, gender, and family history. *Am J Gastroenterol* 1993;88:825-31.
22. Pickhardt PJ. By-patient performance characteristics of CT colonography: importance of polyp size threshold data. *Radiology* 2003;229:291-3.
23. Winawer SJ, Zauber AG. The advanced adenoma as the primary target of screening. *Gastrointest Endosc Clin N Am* 2002;12:1-9.
24. Bond JH. Clinical relevance of the small colorectal polyp. *Endoscopy* 2001;33:454-7.
25. Kulling D, Christ AD, Karaaslan N, Fried M, Bauerfeind P. Is histological investigation of polyps always necessary? *Endoscopy* 2001;33:428-32.
26. Rex DK. Barium studies/virtual colonoscopy: the gastroenterologist's perspective. *Gastrointest Endosc* 2002;55:Suppl: S33-S36. [Erratum, *Gastrointest Endosc* 2002;56:324.]
27. Rex DK, Cutler CS, Lemmel GT, et al. Colonoscopic miss rates of adenomas determined by back-to-back colonoscopies. *Gastroenterology* 1997;112:24-8.
28. Pickhardt PJ. Three-dimensional endoluminal CT colonography (virtual colonoscopy): comparison of three commercially available systems. *AJR Am J Roentgenol* 2003;181:1599-606.
29. McFarland EG. Reader strategies for CT colonography. *Abdom Imaging* 2002;27:275-83.
30. Dachman AH, Kuniyoshi JK, Boyle CM, et al. CT colonography with three-dimensional problem solving for detection of colonic polyps. *AJR Am J Roentgenol* 1998;171:989-95.
31. Macari M, Milano A, Lavelle M, Berman P, Megibow AJ. Comparison of time-efficient CT colonography with two- and three-dimensional colonic evaluation for detecting colorectal polyps. *AJR Am J Roentgenol* 2000;174:1543-9.

Copyright © 2003 Massachusetts Medical Society.

#### PERSONAL ARCHIVES IN THE JOURNAL ONLINE

Individual subscribers can store articles and searches using a feature on the Journal's Web site ([www.nejm.org](http://www.nejm.org)) called "Personal Archive." Each article and search result links to this feature. Users can create personal folders and move articles into them for convenient retrieval later.